

Hormonal and Histological Aspects of Germ Cell Aplasia among a Group of Infertile Men in Gaza Strip

Abdel M. Lubbad^{1,*}

¹Faculty of Medicine, Islamic University of Gaza, Gaza Strip, State of Palestine

Received on (19-5-2014) Accepted on (8-12-2014)

Abstract

Background: Germ cell aplasia is a type of azoospermia characterized by hormonal abnormalities as well as histopathological features.

Objective: To assess hormonal and histological aspects of germ cell aplasia among infertile men in Gaza Strip.

Materials and methods: A total of 375 infertile men visiting the Specialized Medical Centers in Gaza strip were subjected for testicular biopsy. Out of them 74 showed germ cell aplasia. They were interviewed to fill in a questionnaire and blood samples were drawn for determination of testosterone, prolactin, luteinizing hormone (LH) and follicular stimulating hormone (FSH). Forty four fertile men served as controls. Data were computer analyzed using SPSS/ PC, version 18.0.

Results: Germ cell aplasia represented 74 (19.7%) among azoospermic men in Gaza Strip as indicated by testicular biopsy. The mean age of patients and controls was 29.9±5.9 and 31.2±5.7 years, respectively. Medical history showed that varicocele and hormonal problems were significantly higher in patients than controls (P=0.042 and P=0.008, respectively). The number of patients who had abnormal levels of testosterone, prolactin, LH and FSH were 44 (59.5%), 36 (48.6%), 57 (77.0%) and 67 (90.5%) compared to controls of 7 (15.9%), 7 (15.9%), 2 (4.5%) and 13 (29.5%), respectively with $\chi^2=21.326$, P=0.000; $\chi^2=12.098$, P=0.000; $\chi^2=55.122$, P=0.000 and $\chi^2=47.020$, P=0.000, respectively. Testicular biopsy revealed that infertile men with germ cell aplasia showed Sertoli cell only with partial atrophy, Sertoli cell only with Leyding cell hypoplasia and Sertoli cell only with interstitial fibrosis.

Conclusions: Hormonal abnormalities and histopathological features were identified in germ cell aplasia.

Keywords Infertility, Germ cell aplasia, Sex hormones, Testicular biopsy, Gaza Strip.

الجوانب الهرمونية والنسجية في حالات انعدام وجود الخلايا الجرثومية المنتجة للحيوانات المنوية لدى مجموعة من الرجال المصابين بالعقم في قطاع غزة

ملخص

إن انعدام وجود الخلايا الجرثومية المنتجة للحيوانات المنوية (Germ cell aplasia) هو نوع من أنواع العقم المعروف بعدم وجود الحيوانات المنوية في السائل المنوي (azoospermia) والذي يتميز بوجود اضطرابات هرمونية وتغيرات نسيجية.

* Corresponding author e-mail address: alubbad@iugaza.edu.ps

الهدف: تقييم الجوانب الهرمونية والنسجية في حالات انعدام وجود الخلايا الجرثومية المنتجة للحيوانات المنوية لدي مجموعة من الرجال المصابين بالعمق في قطاع غزة.

المواد والطرق: أجريت هذه الدراسة على 375 مريضاً يعانون من العمق ويترددون على المراكز الطبية التخصصية في قطاع غزة وتم أخذ خزعة نسيجية لهم من الخصية، فتبين أن 74 شخصاً منهم لديهم انعدام في الخلايا الجرثومية المنتجة للحيوانات المنوية، وقد أجريت لهؤلاء مقابلة من أجل تعبئة الاستبيان وأخذ عينة دم لفحص هرمون Testosterone وهرمون Prolactin وهرمون Luteinizing hormone وهرمون Follicle stimulating hormone، وتم مقارنة نتائجهم مع 44 عينة من أشخاص لديهم القدرة على الإنجاب (العينة الضابطة)، وتم استخدام برنامج SPSS/ PC الإصدار 18 في تحليل النتائج.

النتائج: أظهرت نتائج الخزعة النسيجية من الخصية أن 74 (19.7%) من الرجال المصابين بالعمق يعانون من حالة انعدام وجود الخلايا الجرثومية المنتجة للحيوانات المنوية وكان متوسط أعمارهم 29.9 ± 5.9 سنة بالمقارنة مع العينة الضابطة 31.2 ± 5.7 سنة. بينت النتائج أن المرضى الذين يعانون من دوالي الخصية والمشاكل الهرمونية كانوا أكثر من أشخاص العينة الضابطة وكانت الفروق ذات دلالة إحصائية ($P=0.042$ ، $P=0.008$ على التوالي). أظهرت النتائج أيضاً أن عدد المرضى الذين لديهم مستويات غير طبيعية في هرمون Testosterone وهرمون Prolactin وهرمون Luteinizing hormone وهرمون Follicle stimulating hormone ($44(59.5\%)$ ، $36(48.6\%)$ ، $57(77.0\%)$ ، $67(90.5\%)$ كان أكثر بفارق ذا دلالة إحصائية مقارنة بالعينة الضابطة ($7(15.9\%)$ ، $7(15.9\%)$ ، $2(4.5\%)$ ، $13(29.5\%)$ على التوالي، $\chi^2=21.326$ ، $P=0.000$ ؛ $\chi^2=12.098$ ، $P=0.000$ ؛ $\chi^2=55.122$ ، $P=0.000$ ؛ $\chi^2=47.020$ ، $P=0.000$ على التوالي). أوضحت نتائج الخزعة النسيجية وجود الضمور الجزئي، وجود النقص في خلايا Leyding ووجود التليف.

الاستنتاج: تم تحديد مستويات غير طبيعية في الهرمونات بالإضافة إلى تغيرات نسيجية لدي المرضى الذين يعانون من انعدام وجود الخلايا الجرثومية المنتجة للحيوانات المنوية.

كلمات مفتاحية: العمق، انعدام وجود الخلايا الجرثومية المنتجة للحيوانات المنوية، هرمونات، خزعة نسيجية من الخصية، قطاع غزة.

1. Introduction

Infertility is a reproductive healthy problem; it is defined as inability to conceive after one year of unprotected intercourse [1]. It affects approximately 10-15% of reproductive age couples [2,3]. One of the causes that contribute to male infertility is germ cell aplasia. Germ cell aplasia applies to a testicle in which germ cells at any stage of maturation are absent, but the tubular architecture is not effaced by fibrosis and supporting cells continue to be present [4].

The etiology of germ cell aplasia is unknown in most cases (Idiopathic), however, Klinefelter syndrome, exposure to chemicals/toxins, hormonal therapy for prostate cancer, viral, orchitis, radiation and

microdeletions of the Y chromosome are the common causes [5,6]. In complete germ cell aplasia the tubules are reduced in diameter, and contain only Sertoli cells but no other cells involved in spermatogenesis [7].

In testicular biopsy of germ cell aplasia the tubular interstitium usually contains variable numbers of Leydig cells. This may contribute to primary testicular failure which is characterized by low testosterone level caused by a deficiency or absence of Leydig cell function, impairment of spermatogenesis, and elevated LH and FSH concentrations [8]. Although such various aspects of germ cell aplasia were globally studied, no previous study investigated or even approached hormonal and histological aspects of germ

cell aplasia among infertile men in Gaza Strip. Therefore, we are in desperate need for such data.

2. Patients and methods

Subjects: A total number of 375 infertile men visiting the Specialized Medical Centers in Gaza strip were subjected for testicular biopsy. They have the history of at least 3 years duration of infertility [9]. Out of them 74 men showed germ cell aplasia. Semen analysis of the 74 germ cell aplasia patients was performed to confirm azoospermia based on World Health Organization criteria [10]. A total number of 44 controls were selected at the basis of being married with at least one child and sperm count >20 million sperm/ml. Patients and controls were age matched. This study was approved by the Ethical Review Board and all participants gave an informed consent.

Questionnaire interview: A face to face interview was used for filling in the questionnaire which is designated for matching the study need. The questionnaire was based on male infertility patient questionnaire with some modification related to medical history [11]. Most questions were the yes/no questions, which offer a dichotomous choice [12]. The questionnaire was validated by six experts in the fields of andrology, urology, and obstetrics and gynecology. The questionnaire was piloted with 10 patients, and modified as necessary to improve reliability. The questionnaire included questions on personal data, sexual history and medical history of both patients and controls.

Testicular biopsy: Incision biopsy was taken by physician, from bilateral testes, then preserved in Bouin's solution as a fixative reagent. Following fixation, dehydration of fixed tissues was done through ascending grades of ethyl alcohol (50%, 70%, 90%, 95% and absolute alcohol). Tissues were then cleared with xylene. This was followed by impregnation with paraffin wax. Having been

completely impregnated, the tissues were embedded in paraffin wax, sectioned by a rotary microtome at a thickness of 3 μm , mounted and affixed to slides. Sections were then stained as a routine in Harris's alum hematoxylin and eosin.

Blood sampling and processing: Venous blood sample (8 ml) was drawn by a well trained medical technologist into vacutainer tubes from each patient and control. Blood left for a while without anticoagulant to allow blood to clot. Then serum samples were obtained by centrifugation at room temperature at 3000 rpm/10 minutes for hormonal assay. Testosterone, prolactin, LH and FSH were determined by enzyme-linked immunosorbent assay, TECO kit, USA.

Statistical analysis: Data were computer analyzed using SPSS/ PC (Statistical Package for the Social Science Inc. Chicago, Illinois USA, version 18.0) statistical package. Simple distribution of the study variables and the cross tabulation were applied. The independent sample t-test procedure was used to calculate the mean ages of patients and controls. Chi-square (χ^2) was used to identify the significance of the relations, associations, and interactions among various variables. Yates's continuity correction test, $\chi^2_{(corrected)}$ was used when not more than 20% of the cells had an expected frequency of less than five and when the expected numbers were small. The results were accepted as statistical significant when the p-value was less than 5% ($P < 0.05$).

3. Results

Testicular biopsy of the 375 infertile men showed that 77 (20.5%) and 298 (79.5%) have obstructive and non-obstructive azoospermia, respectively. The different types of non-obstructive azoospermia were found to be spermatogenesis arrest 126 (33.6%) followed by germ cell aplasia 74 (19.7%), testicular atrophy 53 (14.1%) and finally by hypospermatogenesis 45 (12.0%).

Sexual and medical history of germ cell aplasia patients (n=74) and controls (n=44)

The mean age of germ cell aplasia patients and controls were 29.9±5.9 and 31.2±5.7 years, respectively. As indicated in Table 1, problems with erection or ejaculation as well as trauma showed no significant differences

between patients and controls. However, the number of patients with varicocele and hormonal problems were significantly higher than controls 12 (16.2%) and 19 (25.7%) vs 1 (2.3%) and 2 (4.5%), P=0.042 and P=0.008, respectively.

Item	Patients		Controls		χ^2	P-value*
	No.	%	No.	%		
Sexual history						
Problems with erection						
Yes	7	9.5	1	2.3	1.261	0.261
No	67	90.5	43	97.7		
Problems with ejaculation						
Yes	4	5.4	1	2.3	0.119	0.730
No	70	94.6	43	97.7		
Medical history						
Trauma						
Yes	9	12.2	2	4.5	1.120	0.294
No	65	87.8	42	95.5		
Varicocele						
Yes	12	16.2	1	2.3	4.142	0.042
No	62	83.8	43	97.7		
Hormonal problems						
Yes	19	25.7	2	4.5	7.039	0.008
No	55	74.3	42	95.5		

*p-value of χ^2 (corrected) test, P<0.05: Significant.

Hormonal profile of germ cell aplasia patients and controls

Table 2 shows normal and abnormal hormonal levels of patients and controls in respect to normal reference values. The number of patients who had abnormal levels of testosterone, prolactin, LH and FSH were

44 (59.5%), 36 (48.6%), 57 (77.0%) and 67 (90.5%) compared to controls of 7 (15.9%), 7 (15.9%), 2 (4.5%) and 13 (29.5%), respectively with $\chi^2=21.326$, P=0.000; $\chi^2=12.098$, P=0.000; $\chi^2=55.122$, P=0.000 and $\chi^2=47.020$, P=0.000, respectively.

Table 2 Normal and abnormal hormonal levels of patients (n=74) and controls (n=44) in respect to normal reference values						
Hormone	Patients		Controls		χ^2	P-value
	No.	%	No.	%		
Testosterone (ng/ml)						
Normal	30	40.5	37	84.1	21.326	0.000
Abnormal	44	59.5	7	15.9		
Prolactin (ng/ml)						
Normal	38	51.4	37	84.1	12.098	0.000
Abnormal	36	48.6	7	15.9		
*LH (mIU/ml)						
Normal	17	23.0	42	95.5	55.122	0.000***
Abnormal	57	77.0	2	4.5		
**FSH (mIU/ml)						
Normal	7	9.5	31	70.5	47.020	0.000
Abnormal	67	90.5	13	29.5		

*LH: Lutenizing hormone, **FSH: Follicle stimulating hormone.

Reference values: Testosterone 2.0-7.0 ng/ml; Prolactin 2.0-12.0 ng/ml; Lutenizing hormone 2.0-13.0 mIU/ml; Follicle stimulating hormone 2.5-10.0 mIU/ml.

***p-value of χ^2 (corrected) test, P<0.05: Significant.

Histological profile of germ cell aplasia patients

The results of testicular biopsy revealed that infertile men with germ cell aplasia showed Sertoli cell only with partial atrophy (Figure 1), Sertoli cell only with Leyding cell hypoplasia (Figure 2) and Sertoli cell only with interstitial fibrosis (Figure 3).

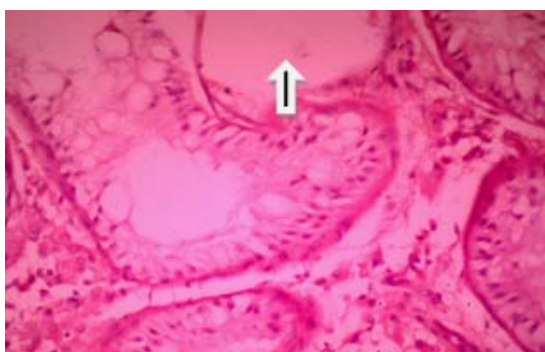


Figure 1 Germinal cell aplasia, Seminiferous tubules showing Sertoli cell only with partial atrophy (arrow), no germ cells noted. Paraffin section, H&E stain, primary magnification, $\times 40$

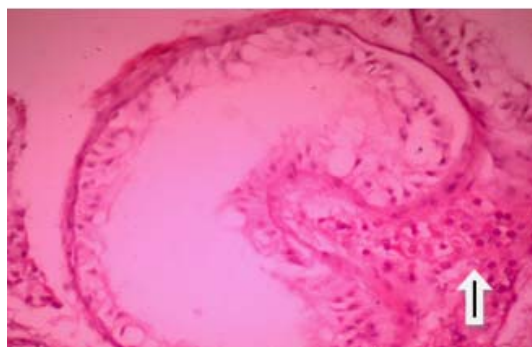


Figure 2 Germinal cell aplasia, seminiferous tubules showing Sertoli cell only with Leyding cell hypoplasia (arrow), no germ cells noted. Paraffin section, H&E stain, primary magnification, $\times 40$.

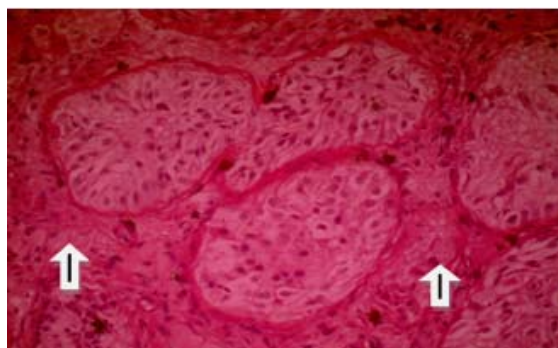


Figure 3 Germ cell aplasia, seminiferous tubules showing Sertoli cell only with interstitial fibrosis

(arrows), no germ cells noted. Paraffin section, H&E stain, primary magnification, $\times 4$

4. Discussion

In Gaza strip there is under-reporting or even no real figures on male infertility particularly azoospermia. Therefore, the present study was aimed to assess for the first time azoospermia focusing on germ cell aplasia in terms of hormonal and histological aspects among infertile men in Gaza Strip. Testicular biopsy showed that almost one fifth (19.7%) of the infertile men have germ cell aplasia. This result is lower than that reported from Egypt [13] and from Yemen [14] where the percentages were 34% and 33.8%, respectively, but higher than that reported from Saudi Arabia [15] where the percentage was 16.5%. This variation may be attributed to social habits, environmental conditions and genetics. The mean age of patients with germ cell aplasia in the present study (29.9 years) was lower than that reported from Nigerian (35.7 years) and Kenyan (36.1 years) studies [16,17]. The younger age of our patient sample could be explained on the basis that most men in Gaza Strip seeking out to have children immediately after marriage.

Sexual history showed no significant difference between patients and controls in terms of problems with erection and ejaculation. The etiology of such problems remains unclear and may not play a major role in male fertility at least in our sample. The erectile function with the ability to engage in normal intercourse was normal in 80% of infertile Iranian men with non-obstructive azoospermia [18]. In this context, [19] found that only one patient (1.3%) out of his study sample of 80 Nigerian infertile men had ejaculation problems. Medical history revealed that the frequency of varicocele was significantly higher in patients compared to controls, implying that varicocele do affect male fertility. It was reported that some cases of male infertility are due to anatomical abnormalities such as varicoceles [20]. In many instances azoospermia was related to the history of varicocele [21-24]. Similarly, hormonal problems were significantly higher

in patients compared to controls, confirming the idea that abnormal spermatogenesis is often associated with altered serum gonadotropins and testosterone [8,9,19].

When compared to the normal reference values, hormonal abnormalities in testosterone, prolactin, LH and FSH levels were significantly higher in patients compared to controls. This supports the previous result that hormonal problems were significantly higher in patients. Similar results were obtained [8,17,19]. The higher prevalence of abnormal hormone levels recorded in patients may refer to germinal epithelial damage associated with germ cell aplasia [25].

The results of testicular biopsy that infertile men with germ cell aplasia showed Sertoli cell only with partial atrophy, Sertoli cell only with Leyding cell hypoplasia and Sertoli cell only with interstitial fibrosis are in agreement with the previous findings [13,26]. These findings reflect the destruction in seminiferous epithelium which may lead to hormonal abnormalities of testosterone, prolactin, LH and FSH observed in the present study. Higher concentration of FSH is considered to be a reliable indicator of germinal epithelial damage, and was shown to be associated with azoospermia and severe oligozoospermia [27-29]. Finally, the overall indication is that histological results are coincide with hormonal changes mentioned earlier in this study i.e. the physiological changes noted in germ cell aplasia are a result of histological changes in seminiferous tubules. Further research is needed to identify the risk factors contributing to germ cell aplasia as well as to assess serum levels of fertility-involved hormones including inhibin.

References

- [1] Kolettis, P. N. Evaluation of the subfertilite man. *American Family Physician*, **67(10)**, (2003) 2165-2172.
- [2] Cerilli, L.A., Kuang, W., and Rogers, D. A Practical approach to testicular biopsy interpretation for male infertility. *Archives of Pathology and Laboratory Medicine*, **134(8)**, (2010) 1197-1204.

- [3] Abu-Halima, M., Hammadeh, M., Schmitt, J., Leidinger, P., Keller, A., Meese, E., and Backes, C. Altered microRNA expression profiles of human spermatozoa in patients with different spermatogenic impairments. *Fertility and Sterility*, **99**(5), (2013) 1249-1255.
- [4] Jain, M., and Halder, A. Sertoli cell only syndrome: Status of sertoli cell maturation and function. *Indian Journal of Endocrinology and Metabolism*, **16**(S2), (2012) S512-513.
- [5] Esteves, S., Miyaoka, R., and Agarwal, A. An update on the clinical assessment of the infertile male. *Clinics*, **66**(4), (2011) 691-700.
- [6] Aksglaede, L., and Juul, A. Testicular function and fertility in men with Klinefelter syndrome. *European Journal of Endocrinology*, **168**(4), (2013) R67-76.
- [7] Nieschlag, E., Behre, H.M., and Nieschlag, S. *Andrology: Male Reproductive Health and Dysfunction*. Third, completely Revised and Updated Edition, Springer Heidelberg Dordrecht London, New York (2010).
- [8] Gudeloglu, A., and Parekattil, S. J. Update in the evaluation of the azoospermic male. *Clinics*, **68**(S1), (2013) 27-34.
- [9] Babu, S. R., Sadhnani, M. D., Swarna, M., Padmavathi, P., and Reddy, P. P. Evaluation of FSH, LH and testosterone levels in different subgroups of infertile males. *Indian Journal of Clinical Biochemistry*, Vol. **19**, (2004) 45-49.
- [10] World Health Organization, *WHO laboratory manual for the examination and processing of human semen*, 5th Edition, Geneva, Switzerland: WHO, (2010).
- [11] Male Infertility Patient Questionnaire Urologic Clinics of North Alabama (2014), Alabama, from http://www.ucna.com/maleinfertility_ucna.pdf visited at 15/03/2014.
- [12] Backstrom, C., and Hursh-César, G., *Survey Research*, Pennsylvania, United States: Literary Licensing, LLC, (2012).
- [13] Rashed, M., Ragab, N., Shalaby, A., and Ragab, W. Patterns of testicular histopathology in men with primary infertility. *The Internet Journal of Urology* (2007) 5-2.
- [14] Al-Samawi, A.S., Al-Malas, N.A., and Jibrel, S.O. Histologic pictures of male infertility in Yemeni patients. *Saudi Medical Journal*, Vol. **30**, (2009) 652-655.
- [15] Abdullah, L., and Bondagji, N. Histopathological patterns of testicular biopsy in male infertility: A retrospective study from a tertiary care center in the western part of Saudi Arabia. *Urology Annals*, **3**(1), (2011) 19-23.
- [16] Muthuuri, J. M. Male infertility in a private Kenyan hospital. *East African Medical Journal*, **82**(7), (2005) 362-366.
- [17] Geidam, A.D., Yawe, K.D., Adebayo, A.E., and Idrisa, A. Hormonal profile of men investigated for infertility at the University of Maiduguri in northern Nigeria. *Singapore Medical Journal*, **49**(7), (2008) 538-541.
- [18] Amirjannati, N., Ghorbani, B., Akhoundi, M.M., Sadeghi, M.R., Jeddi-Tehrani, M., and Soltanghorae, H. Sexual and hormonal profiles of infertile subjects with non-obstructive azoospermia. *Journal of Reproduction and Infertility*, **10**(1), (2009) 42-50.
- [19] Emokpae, M. A., Uadia, P. O., Mohammed, A. Z., and Omale-Itodo, A. Hormonal abnormalities in azoospermic men in Kano, Northern Nigeria. *The Indian Journal of Medical Research*, **124**(3), (2006) 299-304.
- [20] Olayemi, F. O. A review on some causes of male infertility. *African Journal of Biotechnology*, **9**(20), (2010) 2834-2842.
- [21] Inci, K., Hascicek, M., Kara, O., Dikmen, A.V. Gürgan, T., and Ergen, A. Sperm retrieval and intracytoplasmic sperm injection in men with nonobstructive azoospermia, and treated and untreated varicocele. *The Journal of Urology*, **182**(4), (2009) 1500-1505.
- [22] Weedon, J. W., Khera, M., and Lipshultz, L. I. Varicocele repair in patients with nonobstructive azoospermia: a meta-analysis. *The Journal of Urology*, **183**(6), (2010) 2309-2315.

- [23] Inci, K., and Gunay, L. M. The role of varicocele treatment in the management of non-obstructive azoospermia. *Clinics*, **68(S1)**, (2013) 89-98.
- [24] Jungwirth, A., Diemer, T., Dohle, G. R., Giwercman, A., Kopa, Z., Tournaye, H., and Krausz, C. Guidelines on male infertility. Arnhem (The Netherlands): European Association of Urology (2013) 60.
- [25] Bergmann, M., Behre, H., and Nieschlag, E. Serum FSH and testicular morphology in male infertility. *Clinical Endocrinology*, Vol. **40**, (2008) 133-136.
- [26] Razak, A.H., Testicular biopsy in azoospermia man: a study of the morphological patterns in Duhok city and attempt toward the development of a new evaluation system. *Duhok Medical Journal*, **6(2)**, (2012) 53-60.
- [27] Chen, S., Hsieh, J., Yu, H., and Chang, H. Appropriate cut-off value for follicle-stimulating hormone in azoospermia to predict spermatogenesis. *Reproductive Biology and Endocrinology*, Vol. **8**, (2010) 108.
- [28] Gordetsky, J., van, Wijngaarden, E., and O'Brien, J. Redefining abnormal follicle-stimulating hormone in the male infertility population. *British Journal of Urology International*, **110(4)**, (2012) 568-572.
- [29] Wang, L., Huang, H., Jin, F., Zhou, C., Qian, Y., and Chen, J. High expression of follicle stimulating hormone receptor in testicular tissue of idiopathic azoospermic patients with severe spermatogenic defects. *Chinese Medical Journal*, **127(3)**, (2014) 488-493.